

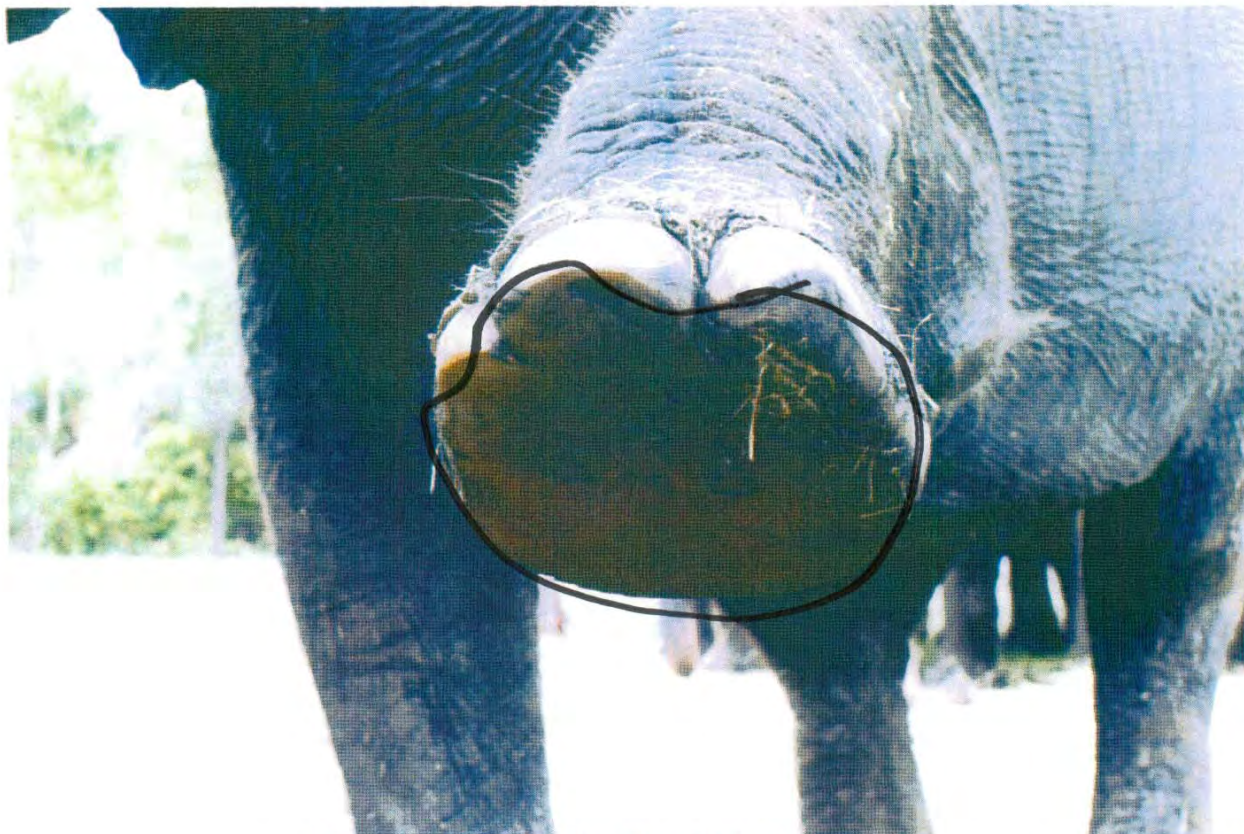Fig. 47- PL 15381 Sole of Jewell's left front foot.

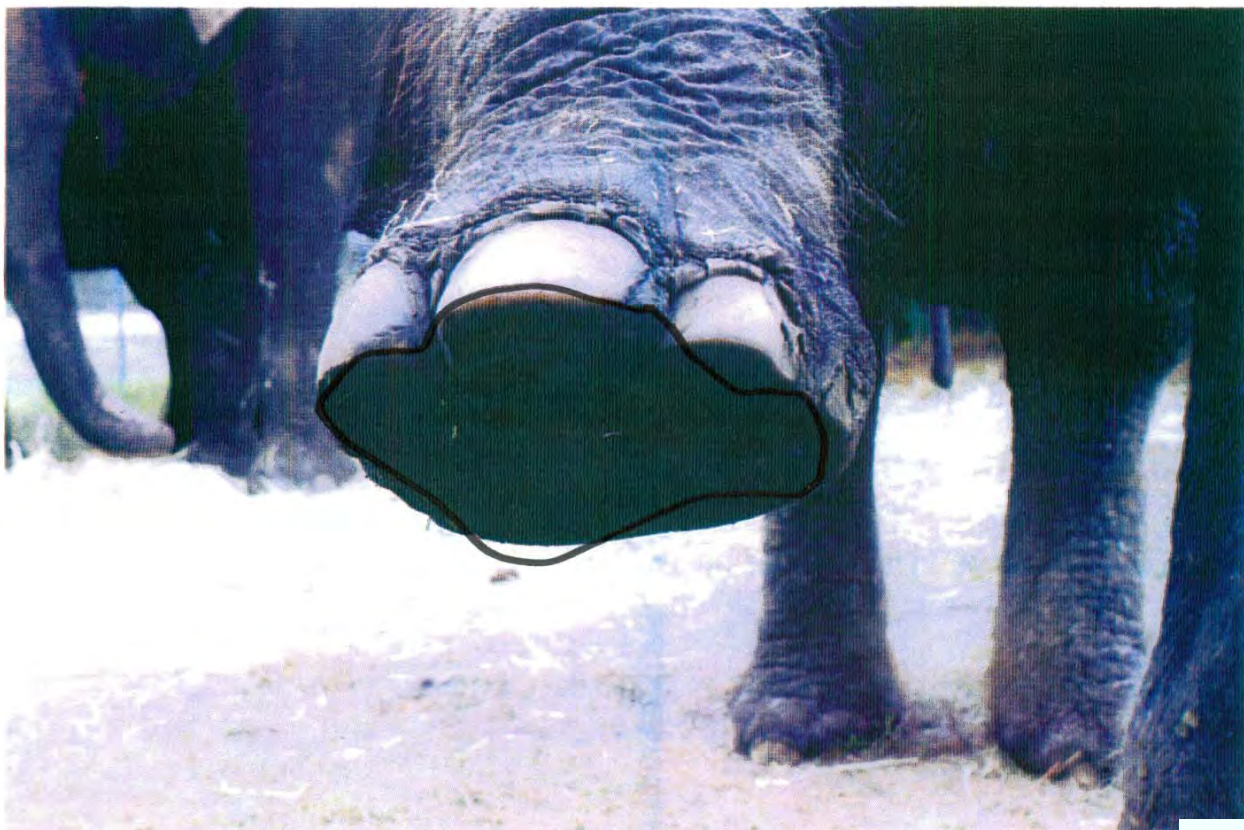


Fig. 46- PL 15386 Sole of Jewell's right front foot.

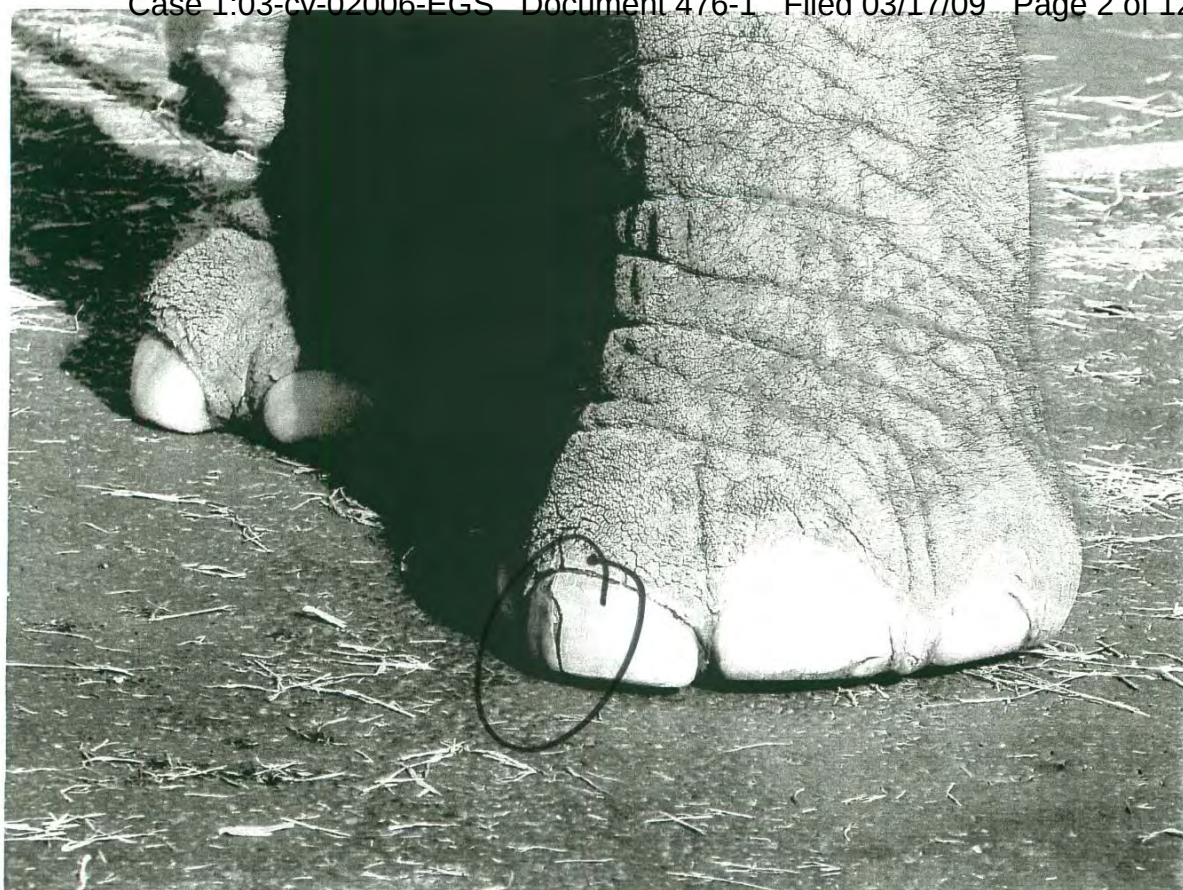


Fig. 20- PKE 125 Toe nail crack partially closed.

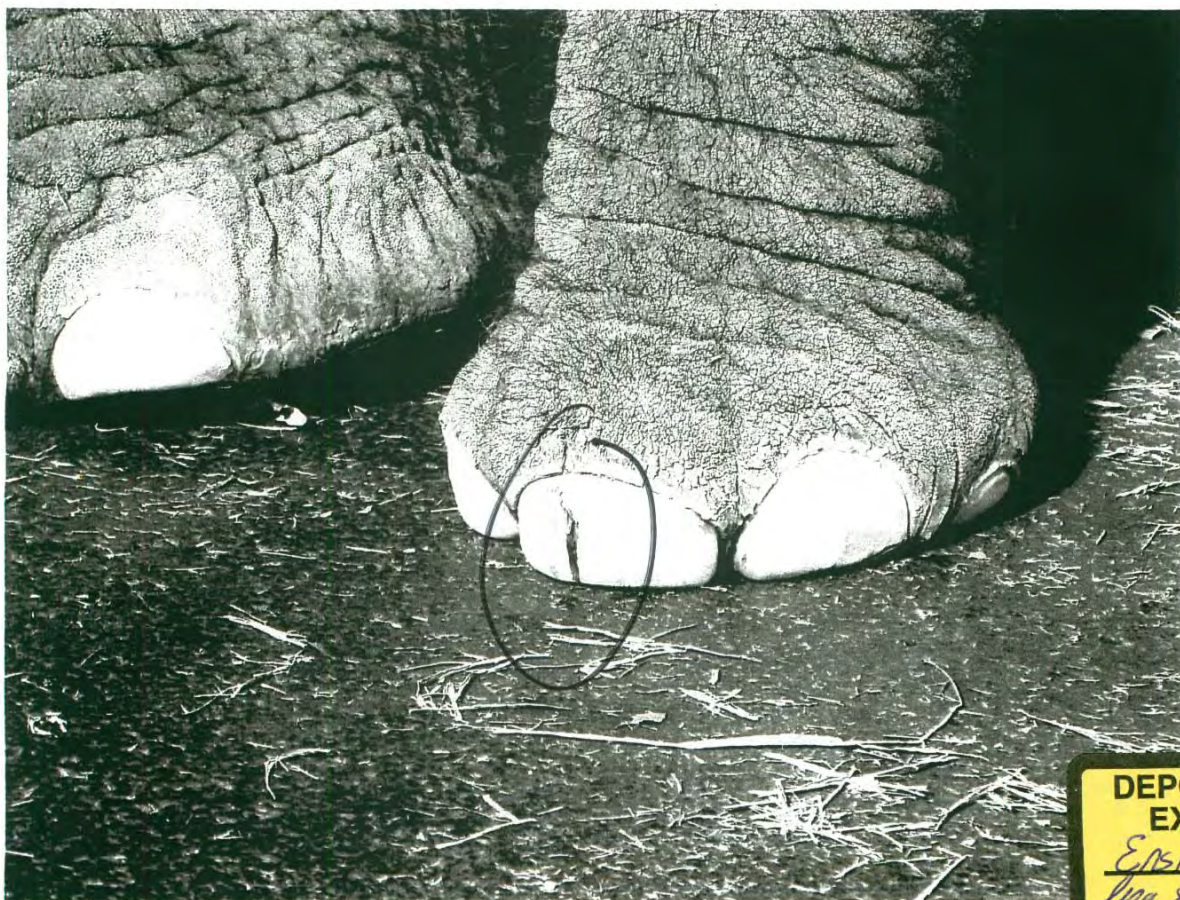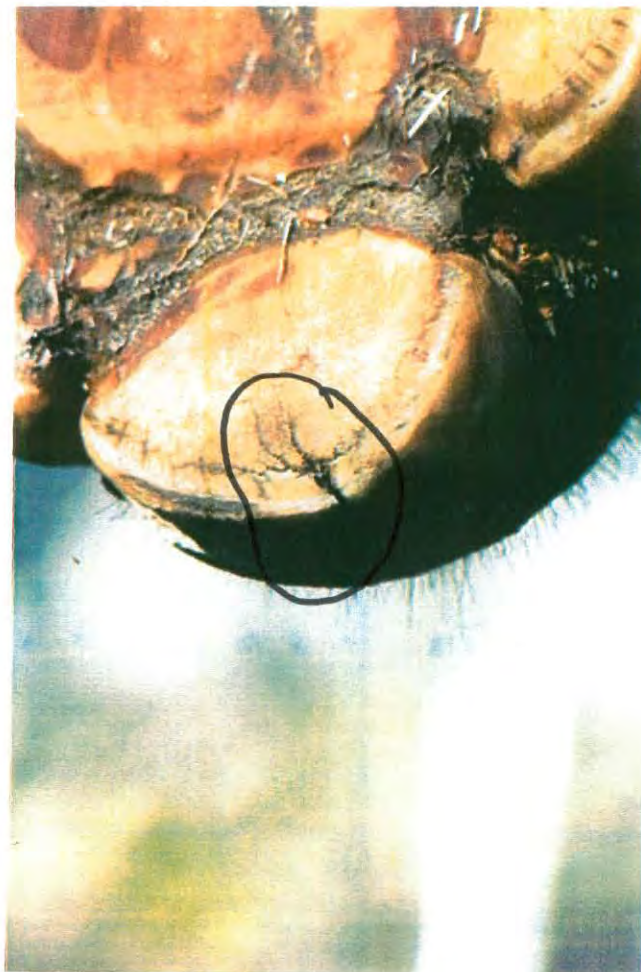


Fig. 19- PKE 126 Toe nail crack spread open with more weight on foot.

DEPOSITION
EXHIBIT
Ensley II
born 8/25/08



Fig. 17- PL 15024 Toe nail crack seen from the bottom of Karen's left foot.



DEPOSITION
EXHIBIT
Ersley 12
Lwa 8/25/08

Fig. 18- PL 15037 Closer view of toe nail crack.

Fig. 15- PKE 118 Uneven wear pattern on the sole of Karen's left rear foot.

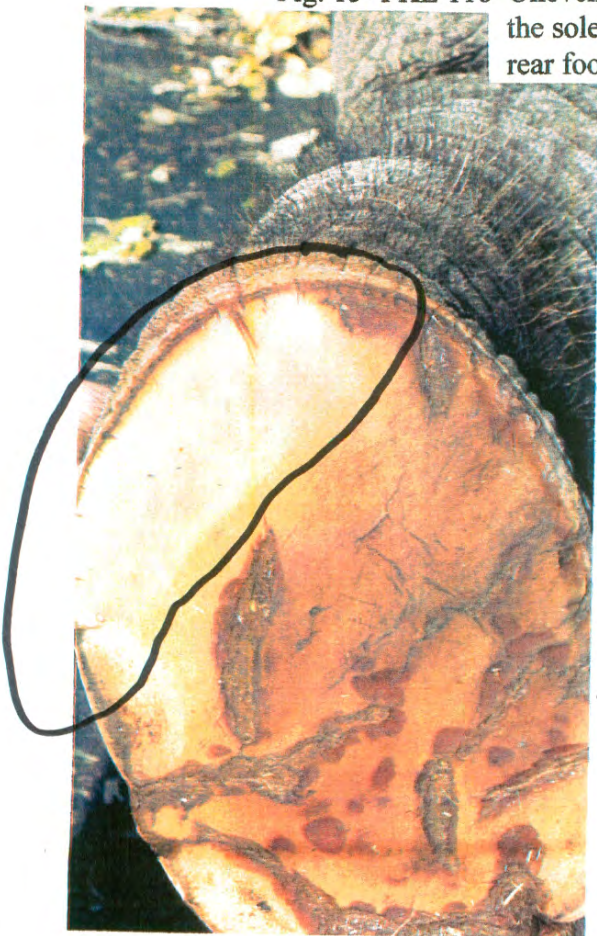

Fig. 16- PKE 120 Uneven wear pattern on the sole of Karen's right rear foot.

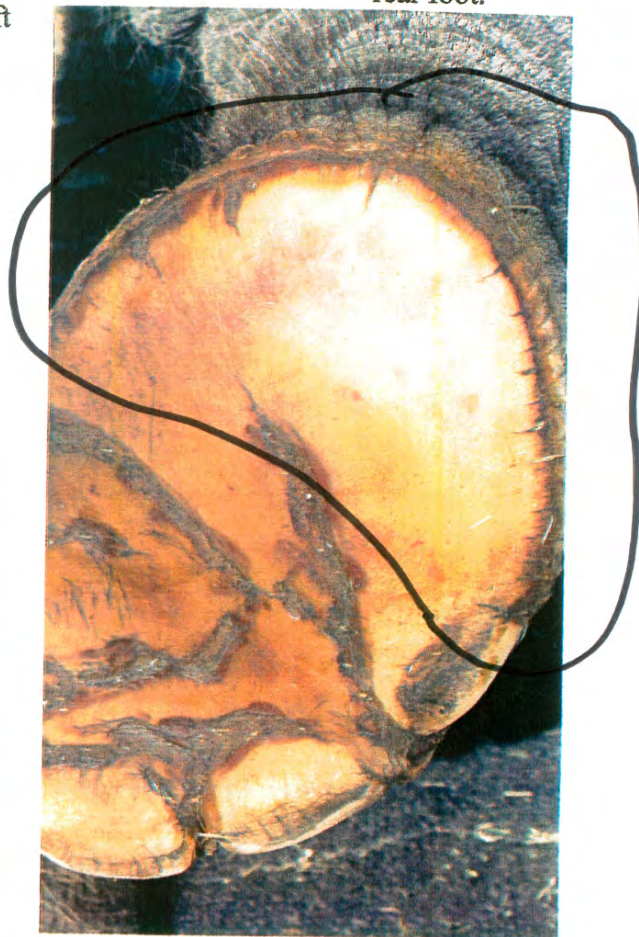


Fig. 24- PKE 122 Callous in front of Karen's right knee.



Fig. 23- PKE 133 Callouses behind Karen's left elbow and left knee.

DEPOSITION
EXHIBIT
Ensley 14
Dora 8/25/08



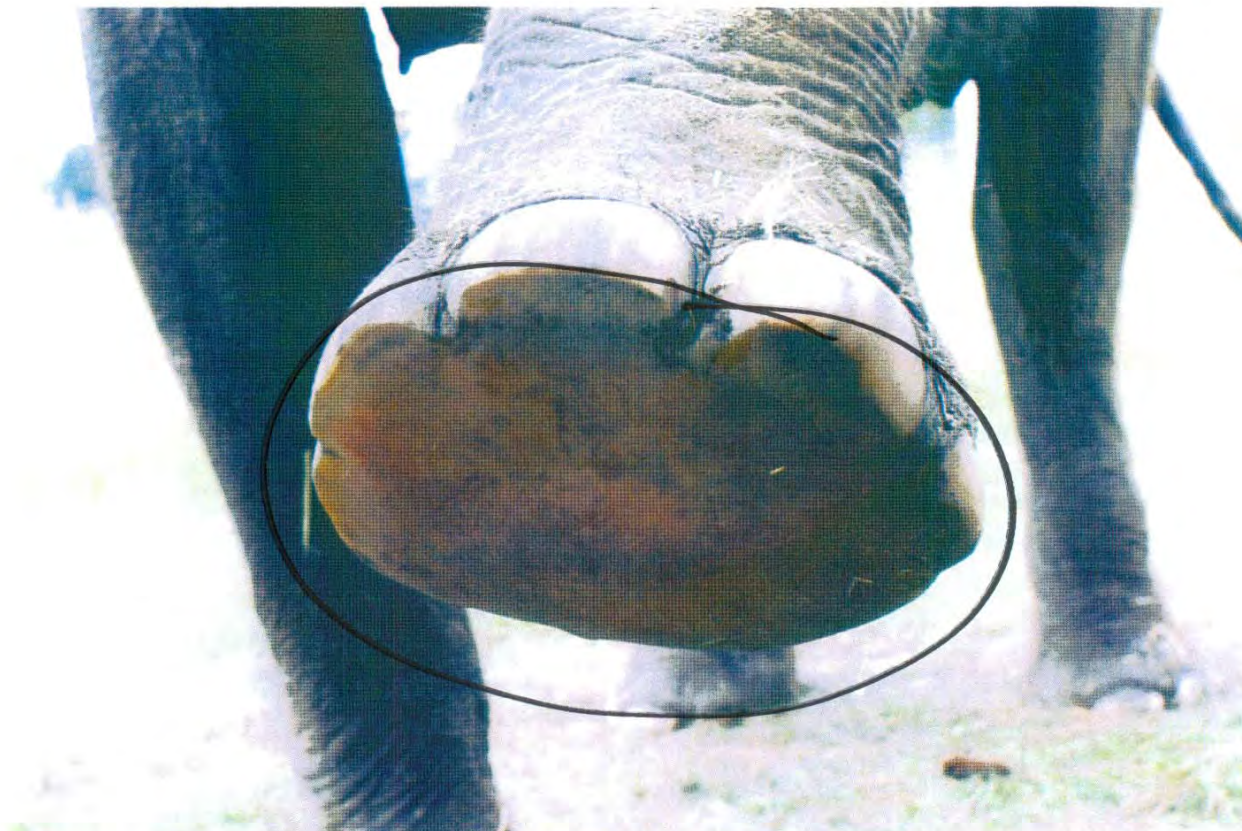


Fig. 48- PL 15447 Sole of Lutzi's left front foot.

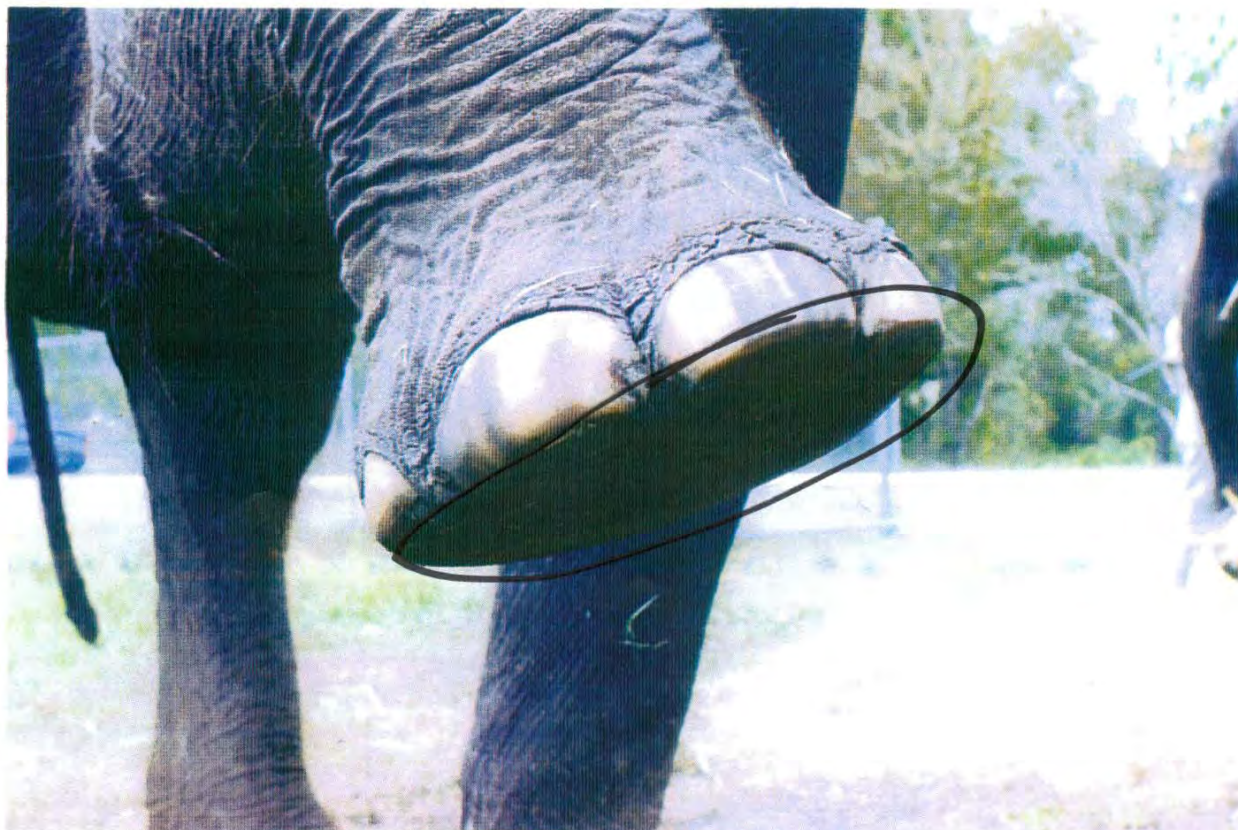

Fig. 49- PL 15451 Sole of Lutzi's right front foot.

cracks present but not seen

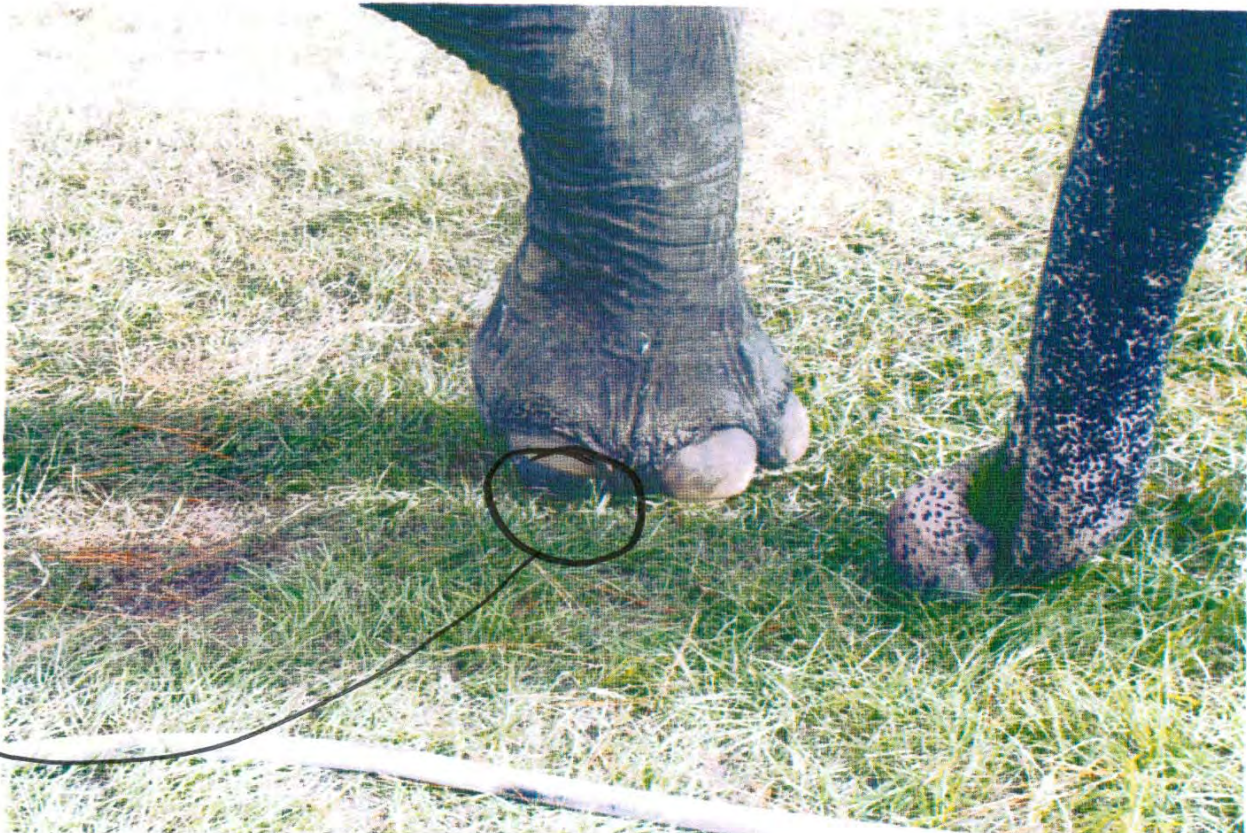


Fig. 36- PL 15162 Toe nail cracks on Mysore.



Fig. 35- PL 15179 Callous on Mysore's left elbow and
hump on lateral aspect of the left cornea

Fig. 10- PKE 093 Asian elephant Nicole's rear feet were unevenly worn.



DEPOSITION
EXHIBIT
Enslley / S
LCA 8/25/08

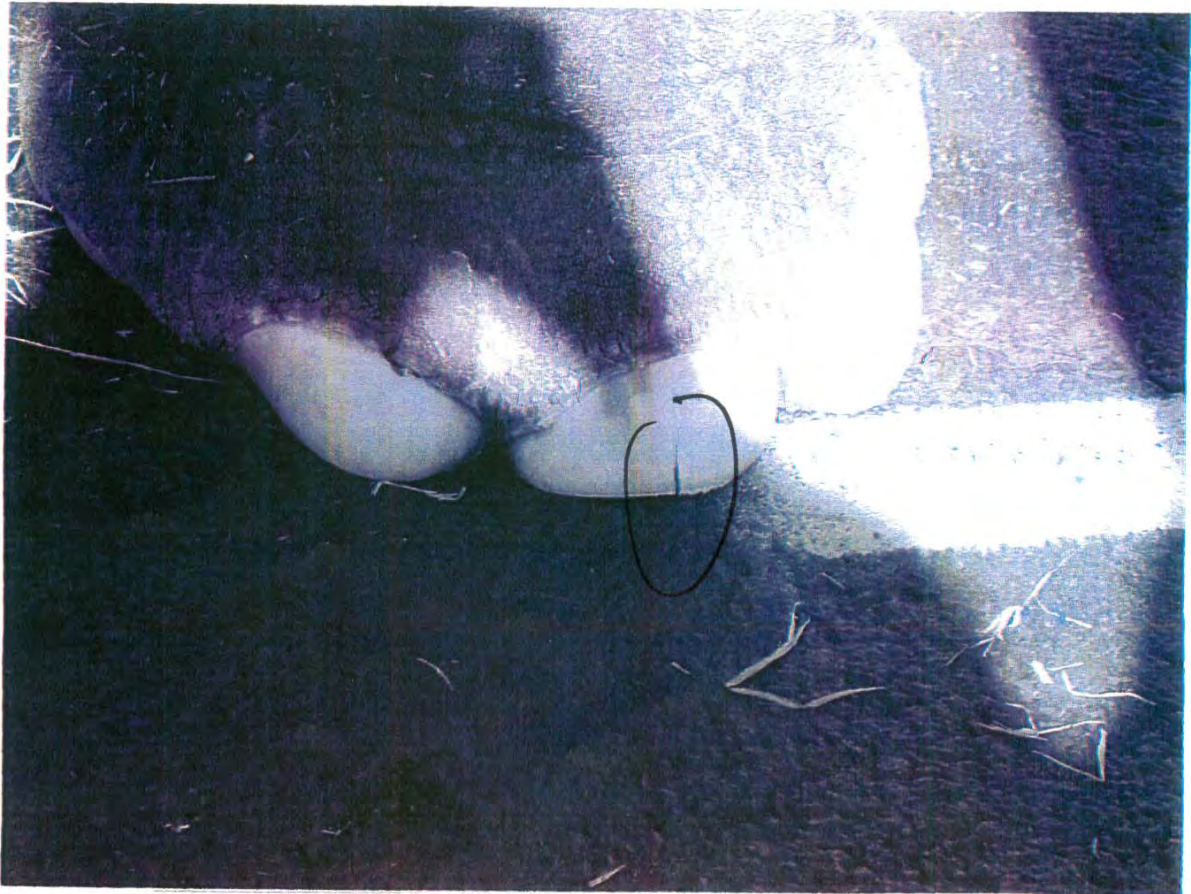


Fig. 11- PKE 096 Vertical toe nail crack on Asian elephant Nicole

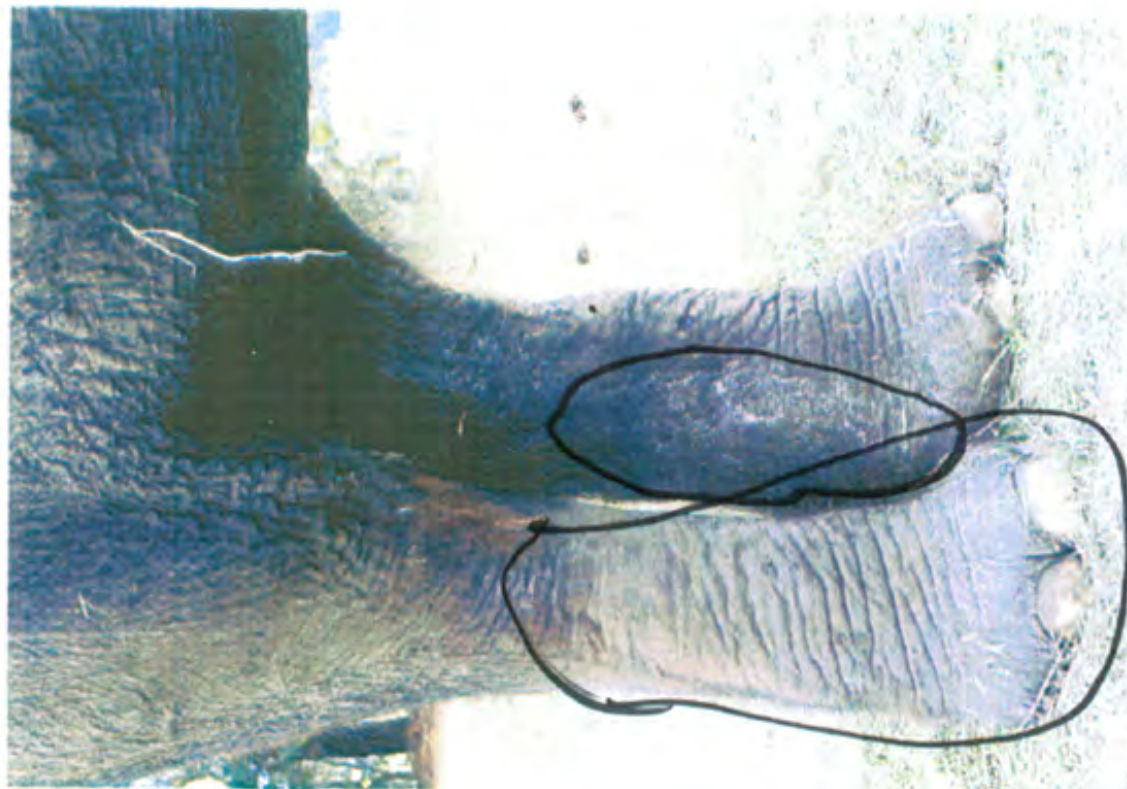


Fig. 43- PL 15367 Scar tissue on inner aspect of left rear leg.

Fig. 42- PL 15359 Scar tissue on inner and rear aspect of left rear leg.






Fig. 45- PL 15320 Chronic toe nail abscess on Susan's right front foot.




Fig. 44- PL 15328 Chronic toe nail abscess on Susan's left front foot.



Fig. 37- PL 15269 Scar tissue on leg compatible with chain trauma.

ZINA

DEPOSITION
EXHIBIT
Emsley 9
Ana 8/25/08



Fig. 39- PL 15301 Sole of Zina's right front foot.



Fig. 38- PL 15298 Sole of Zina's left front foot.

Fig. 40- PL 15312 Sole of Zina's left rear foot.

